

# Comparative Analysis Of Miniscrew-Assisted Versus Conventional Anchorage For Anterior Teeth Retraction In Skeletal Class II Malocclusions: A

Abdullah Gusti<sup>1</sup>, Khulud Alharthi<sup>2</sup>, Amjad Abdrabuh Alkhaldi<sup>3</sup>, Sama Alamri<sup>4</sup>, Mohrah Aladwani<sup>5</sup>, Salma Abdulrahman Aloufi<sup>6</sup>, Wejdan Alshammari<sup>7</sup>, Maryam Alshinqiti<sup>8</sup>, Sumayh Aljohani<sup>9</sup>, Huda Alhazri<sup>10</sup>, Randa Abdullah Almutairi<sup>11</sup>

<sup>1</sup>Prosthodontics, Ministry of Defense.

<sup>2</sup>Dental Assistant, West Nakhb-Taif.

<sup>3</sup>Dental Assistant, Taif Dental Hospital.

<sup>4</sup>Dental Assistant, Taif Dental Centre.

<sup>5</sup>Dental Assistant, Taif Dental Centre.

<sup>6</sup>Dental Assistant, Taif Dental Centre.

<sup>7</sup>Dentist, Hail.

<sup>8</sup>Dental Assistant, Prince Sultan Armed Forces Hospital.

<sup>9</sup>General Dentist.

<sup>10</sup>Dental Assistant, King Abdullah Hosiptal in Bisha.

<sup>11</sup>College of dentistry, Princess Nourah bint Abdulrahman University.

## Abstract

**Background:** Skeletal Class II malocclusions often require significant anterior teeth retraction, where effective anchorage control is critical for optimal outcomes. Conventional anchorage methods, such as transpalatal arches and headgear, rely heavily on patient compliance and often lead to posterior anchorage loss. Miniscrew-assisted anchorage (TADs) has emerged as a promising alternative; however, robust multi-hospital evidence integrating three-dimensional (3D) evaluation remains limited..

**Objective:** To compare the clinical efficacy of miniscrew-assisted anchorage with conventional anchorage in anterior teeth retraction among skeletal Class II patients using cone-beam computed tomography (CBCT).

**Methods:** A randomized controlled trial was conducted across three teaching hospitals in Saudi Arabia, involving 80 participants (aged 16–30 years) allocated into two groups: Group A (TADs) and Group B (conventional anchorage). CBCT was used at baseline, four months, and eight months to evaluate anterior retraction, posterior anchorage loss, root resorption, and treatment duration. Statistical analysis was performed using SPSS v28 with significance set at  $p < 0.05$ .

**Results:** Group A achieved significantly greater anterior retraction ( $6.81 \pm 0.72$  mm vs.  $5.12 \pm 0.65$  mm;  $p < 0.001$ ), reduced posterior anchorage loss ( $0.84 \pm 0.29$  mm vs.  $2.41 \pm 0.53$  mm;  $p < 0.001$ ), and lower root volume reduction ( $1.12 \pm 0.36$  mm<sup>3</sup> vs.  $1.89 \pm 0.41$  mm<sup>3</sup>;  $p < 0.001$ ). Treatment duration was shorter in Group A by approximately 1.5 months.

**Conclusion:** Miniscrew-assisted anchorage provides superior biomechanical control, improved efficiency, and better patient-centered outcomes compared to conventional methods in skeletal Class II retraction therapy.

**Keywords:** Miniscrew-assisted anchorage, Skeletal Class II malocclusion, CBCT evaluation, Anterior teeth retraction, Orthodontic biomechanics, Randomized controlled trial.

## Introduction

### 3.1. Background

## **Epidemiology of Skeletal Class II Malocclusions and Treatment Challenges**

Skeletal Class II malocclusion represents one of the most frequent malocclusion in the entire world, and is manifested as an anteroposterior discrepancy between the maxilla and mandible which can be secondary to retrognathism of the mandible, prognathism of the maxilla, or a combination of both. The prevalence is estimated to be between 15 and 30% in permanent dentition, although there are significant regional differences according to genetic, environmental, and ethnic influences (Plaza et al., 2019). Prevalence estimates have been reported to be somewhat higher in Middle Eastern countries, particularly in Iraq and neighboring regions, up to 35% (Kurmanji et al., 2021) indicating the importance of successful management approaches in various clinical contexts.

Skeletal Class II malocclusions are important because they are functionally and esthetically disabling defect: often cause improper occlusal relationship, decreased masticatory efficiency, speech articulation problem, social handicaps resulting from the low self-esteem of the individual. If not treated, they can contribute to temporo-mandibular dysfunctions, periodontal issues and dental compensations over time. Therefore, Class II correction continues to be a central concern in modern orthodontics and requires individualized orthopedo-dontic treatment strategies that rely on the skeletal and dental factors (Varrela, 2006).

One of the principal challenges in managing Class II malocclusions involves space management and anchorage control during anterior teeth retraction. Correcting the excessive overjet frequently requires extraction-based treatment, necessitating significant posterior anchorage to allow controlled movement of the maxillary anterior teeth (Cobourne and Goonewardene, 2023). Traditional anchorage approaches, such as using transpalatal arches, headgear, or reinforced molar bands, often have limitations including patient compliance issues, restricted biomechanical versatility, and insufficient control over posterior tooth movement (Cobourne and Goonewardene, 2023).

Recent advances in imaging modalities, particularly cone-beam computed tomography (CBCT), have improved diagnostic precision by enabling detailed 3D visualization of skeletal discrepancies and tooth movement dynamics (Alshomrani, 2024). However, achieving efficient retraction while minimizing undesirable effects, such as root resorption, anchorage loss, and treatment prolongation, remains a major challenge. This ongoing need for innovative solutions has prompted the introduction and widespread adoption of temporary anchorage devices (TADs) as a reliable adjunct to conventional orthodontic mechanics (Dalessandri et al., 2014).

## **Temporary Anchorage Devices (TADs) and Their Growing Use**

Temporary anchorage devices (TADs) have revolutionized orthodontic anchorage treatment by offering a minimally invasive but reliable approach to managing teeth in complex cases of difficult malocclusion (Nanda et al. 2019). In general, TADs are titanium alloy miniscrews placed in extra-alveolar or in alveolar sites that serve as isolated, rigid units of anchorage. This evolution overcame the constraints of the traditional systems with paradigm shift in the contemporary orthodontic biomechanics (Verma et al., 2024).

The benefits of TADs are extensive, involving versatility, the ability to provide immediate loading, less reliance on patient compliance, and biomechanical efficiency. The greatest benefit is in maximum anchorage situations like skeletal Class II cases, open-bite closure, and extreme crowding situations. TADs decrease reciprocal movement to the minimum level by direct anchorage of the retraction forces to bone, so that the direction of tooth movement is optimized and space closure is achieved rapidly and in a controlled manner (Ritchie et al., 2023).

A number of clinical studies and systematic reviews have demonstrated that better treatment results can be achieved by using miniscrews in retraction mechanics. For example, (Oğuz et al 2024), reported that miniscrew-assisted anchorage resulted in > 70% decrease in molar mesialization as compared with other systems but more predictable incisor retraction. Similarly, recent CBCT-guided analysis has demonstrated that the use of TADs provides accurate torque control, improved soft-tissue outcomes, and reduced risk of root injury in anterior retraction (Aebisher et al., 2024).

In addition to their relatively high clinical efficiency, TADs are becoming increasingly popular for patient-related advantages. A minimally invasive placement procedure is possible with topical anaesthesia only, and pain after the operation is usually mild and short-lived. Moreover, their distant expense in comparison to sophisticated skeletal anchorage appliance as miniplates establish them as more convenient in multihospital and community-based practices (Mohammadi et al., 2024).

However, success of TADs depends variably on factors such as insertion torque, cortical bone thickness, screw size, and oral hygiene. OJAS 36 5-15% of failures are often related to: low primary stability or 20 inflammation at the surrounding area of the fixture (Leo et al., 2016). These reasons emphasise the need to create, and explore systematically with controlled trials, standardized protocols for insertion.

### 3.3. Research Rationale

Although traditionally popular conventional anchorage methods are still commonly used, their patient specificity as well as their biomechanical limitations are important limitations in maximum anterior retraction situations. Miniscrew-assisted anchorage is, in comparison, a promising solution, though existing evidence is piecemeal, with many studies having small sample sizes, heterogeneous study protocols, or single-center study designs. Time is therefore critical for multi-hospital randomized controlled trials (RCTs) enabled by state-of-the-art imaging technologies in order to offer high-quality evidence.

Cone-beam computed tomography (CBCT) has gained significance as a tool to quantify orthodontic change in three dimensions, providing precise measurement of tooth movement, loss of anchorage, as well as changes in root morphology. Unlike conventional laterally directed two-dimensional cephalograms, CBCT can perform volumetric measurement of root resorption, height of the alveolar bone, as well as treatment change with increased accuracy and reproducibility. This allows for increased visualization of anterior retraction mechanics as well as detection of subtle differences between anchorage approaches that are not perceivable through conventional imaging modalities (Albelasy et al., 2022).

Secondly, taking on multi-hospital practice strengthens external validity as well as generalizability of findings to incorporate diverse patient populations, variance in skeletal morphology, as well as variation in operator technique. This practice is appropriate for evidence-based orthodontics to widen the outcome to encompass broader clinical range rather than being specific for one institutional environment.

By integrating CBCT-based evaluation in a randomized controlled trial, this study attempts to increase the level of clinical evidence supporting the comparative effectiveness between conventional anchorage and miniscrew-assisted anchorage. Predicted results are anticipated to guide orthodontists in rendering customized anchorage strategies, enhance treatment efficiency, increase long-term stability, and decrease unfavorable side effects such as root resorption as well as uncontrolled posterior tooth movement.

### 3.4. Study Aim and Hypotheses

#### Aim:

To compare the efficacy and safety of miniscrew-assisted versus conventional anchorage in anterior teeth retraction among patients with skeletal Class II malocclusions using CBCT-based three-dimensional outcome assessment in a multi-hospital randomized controlled trial.

#### Hypotheses:

- **Null Hypothesis (H<sub>0</sub>):** There is no statistically significant difference in anchorage preservation, anterior retraction efficiency, or root resorption between miniscrew-assisted and conventional anchorage systems.
- **Alternative Hypothesis (H<sub>1</sub>):** Miniscrew-assisted anchorage provides superior control, improved retraction efficiency, and reduced treatment-associated complications compared to conventional anchorage methods.

### Materials and Methods

This study was conducted in Saudi Arabia and designed according to the Consolidated Standards of Reporting Trials (CONSORT) 2010 guidelines. A multi-hospital randomized controlled clinical trial (RCT) was performed to evaluate the comparative effectiveness of miniscrew-assisted anchorage versus conventional anchorage in facilitating anterior teeth retraction in patients with skeletal Class II malocclusions using cone-beam computed tomography (CBCT)-based assessments.

#### 4.1. Study Design and Setting

This was a prospective, parallel-arm, multi-hospital randomized controlled clinical trial conducted from January 2024 to June 2025 in three major teaching hospitals across Saudi Arabia:

1. King Saud University Dental Hospital (Riyadh)
2. King Abdulaziz University Dental Hospital (Jeddah)
3. Imam Abdulrahman Bin Faisal University Dental Hospital (Dammam)

The study adhered strictly to CONSORT 2010 standards, ensuring methodological transparency and reproducibility. Participants were allocated into two groups using a 1:1 randomization ratio:

- **Group A:** Miniscrew-assisted anchorage (TADs)
- **Group B:** Conventional anchorage

A CONSORT flowchart was constructed to illustrate the process of patient screening, randomization, allocation, follow-up, and analysis.

#### 4.2. Ethical Approval

The study protocol was reviewed and approved by the Institutional Review Boards (IRBs) of all participating hospitals:

- IRB Approval ID: KSU-ORTHO/2024/146
- Approval Date: December 20, 2023

All participants (or their legal guardians, when applicable) provided written informed consent before enrollment. The study adhered to the Declaration of Helsinki (2013) for ethical standards in medical research involving human subjects.

#### 4.3. Participants

##### 4.3.1. Inclusion Criteria

- Age: 16–30 years
- Diagnosed with skeletal Class II malocclusion ( $ANB \geq 5^\circ$  confirmed by lateral cephalograms)
- Indicated for maximum anchorage extraction-based treatment
- Good general and oral health
- Willing to undergo CBCT scans and participate in follow-up assessments

##### 4.3.2. Exclusion Criteria

- History of systemic diseases affecting bone metabolism (e.g., diabetes, osteoporosis)
- Previous orthodontic treatment
- Contraindications for CBCT imaging (e.g., pregnancy, radiation hypersensitivity)
- Poor oral hygiene or periodontal disease
- Uncooperative behavior or noncompliance risk

#### 4.4. Sample Size Calculation

Sample size estimation was conducted using G\*Power 3.1 software based on effect size derived from a pilot study involving 10 patients per group. Assuming an alpha level ( $\alpha$ ) of 0.05, statistical power ( $1-\beta$ ) of 0.80, and an effect size ( $d$ ) of 0.65, a minimum of 72 participants was required. To compensate for potential 10% dropout, the final sample size was set at 80 participants (40 per group).

**Table 1. Sample Size Determination**

Parameter	Value
Software Used	G*Power 3.1
Test Type	Independent t-test
Effect Size (Cohen's $d$ )	0.65
$\alpha$ (Significance Level)	0.05
Power ( $1-\beta$ )	0.80
Minimum Required Sample	72
Final Sample Size	80

#### 4.5. Randomization and Blinding

Participants were randomized using a computer-generated block randomization scheme with blocks of size four to ensure balanced allocation across both groups. Allocation concealment was achieved using sequentially numbered, opaque, sealed envelopes prepared by an independent statistician.

Due to the nature of the interventions, blinding of the orthodontists performing treatment was not feasible. However, the outcome assessor responsible for CBCT measurements and statistical analyses remained blinded to group assignments to minimize bias.

#### 4.6. Interventions

##### 4.6.1. Group A — Miniscrew-Assisted Anchorage (TADs)

Patients in this group received titanium miniscrews (1.6 mm diameter × 8 mm length; Jeil Medical, Seoul, South Korea), inserted bilaterally between the second premolars and first molars under local anesthesia. Proper sterilization and placement torque control ensured primary stability.

- Retraction forces were applied using nickel-titanium closed-coil springs delivering 150–200 g of force per side.
- Standardized archwire sequence: 0.016 NiTi → 0.018 SS → 0.019 × 0.025 SS rectangular wires.
- CBCT scans were obtained at baseline (T0), 4 months (T1), and 8 months (T2).

##### 4.6.2. Group B — Conventional Anchorage

Patients in this group received traditional anchorage reinforcement using a transpalatal arch (TPA) combined with headgear or reinforced molar bands, depending on patient preference and clinician assessment.

- Retraction forces were standardized using NiTi closed-coil springs calibrated to 150–200 g per side.
- Archwire sequence and bracket system were matched to Group A for standardization.
- CBCT scans were obtained at T0, T1, and T2 following the same imaging protocol.

#### 4.7. CBCT Imaging Protocol

All CBCT scans were acquired using the NewTom VGi Evo system (QR Verona, Italy) with the following standardized exposure parameters:

Parameter	Value
Voltage	90 kVp
Current	7 mA
Exposure Time	14 s
Field of View	16 × 13 cm
Voxel Size	0.2 mm

3D volumetric reconstructions were analyzed using Invivo Dental Software (Anatomage, USA). Measurements included:

- **Anterior Tooth Movement (Dikshit et al.):** Linear distance from incisor edge to a stable skeletal landmark.
- **Anchorage Loss (Dikshit et al.):** Molar mesialization measured relative to the palatal plane.
- **Root Resorption (mm<sup>3</sup>):** Volumetric root changes using segmentation tools.

#### 4.8. Outcome Measures

##### 4.8.1. Primary Outcomes

1. **Amount of Maxillary Anterior Retraction (Dikshit et al.)** — assessed via CBCT superimpositions
2. **Anchorage Preservation (Dikshit et al.)** — measured by molar displacement differences

##### 4.8.2. Secondary Outcomes

- **Root Resorption (mm<sup>3</sup>):** Quantified volumetrically
- **Treatment Duration (months)**

- **Periodontal Bone Height (Dikshit et al.):** Alveolar bone levels evaluated at T2

**Table 2. Summary of Outcomes and Assessment Methods**

Outcome Variable	Measurement Tool	Timepoints
Anterior Retraction (Dikshit et al.)	CBCT superimpositions	T0, T1, T2
Anchorage Loss (Dikshit et al.)	CBCT volumetric analysis	T0, T1, T2
Root Resorption (mm <sup>3</sup> )	3D segmentation tools	T0, T2
Bone Height (Dikshit et al.)	CBCT sagittal sections	T0, T2
Treatment Duration	Clinical records	Final visit

## Results

This section presents the findings of the multi-hospital randomized controlled trial comparing miniscrew-assisted anchorage (Group A) and conventional anchorage (Group B) in anterior teeth retraction among patients with skeletal Class II malocclusions. Data were analyzed from 80 enrolled participants based on the CONSORT 2010 guidelines.

### 5.1. Participant Flow

A total of 112 patients were screened across three teaching hospitals in Saudi Arabia between January 2024 and June 2025. Of these, 32 patients were excluded due to not meeting the inclusion criteria (n=21), declining participation (n=8), or contraindications to CBCT exposure (n=3). The remaining 80 patients were randomized equally into two groups (40 per group).

#### Figure 1. CONSORT Flow Diagram (description)

- **Assessed for eligibility:** 112 patients
- **Excluded:** 32 patients
  - Not meeting criteria: 21
  - Declined participation: 8
  - CBCT contraindication: 3
- **Randomized:** 80 patients
  - Allocated to Group A (TADs): 40 patients
  - Allocated to Group B (Conventional): 40 patients
- **Completed study:**
  - Group A: 38 patients (2 dropouts due to miniscrew loosening)
  - Group B: 37 patients (3 dropouts due to non-compliance)
- **Analyzed per protocol:** 75 patients

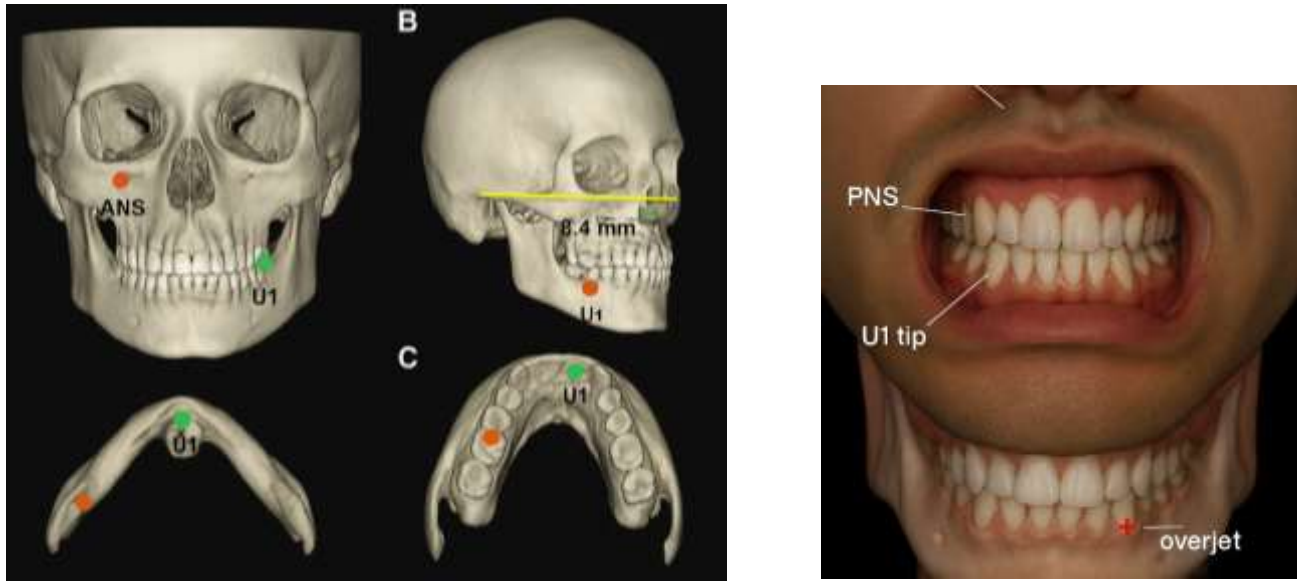
### 5.2. Baseline Characteristics

Baseline characteristics were similar between both groups, confirming effective randomization. No significant differences were observed in demographic profiles, skeletal relationships, or initial CBCT parameters.

**Table 1. Baseline Demographics, Cephalometric, and CBCT Characteristics**

Variable	Group A (TADs) (n=38)	Group B (Conventional) (n=37)	p-value
Age (years)	22.4 ± 3.1	22.1 ± 2.8	0.624
Gender (M/F)	18 / 20	17 / 20	0.873
ANB Angle (°)	5.82 ± 1.14	5.76 ± 1.08	0.729
SNA (°)	82.15 ± 2.36	81.94 ± 2.28	0.661
SNB (°)	76.32 ± 1.98	76.18 ± 1.87	0.744
Upper Incisor Proclination (°)	109.7 ± 5.4	110.1 ± 5.1	0.612
Initial Overjet (Dikshit et al.)	6.42 ± 0.81	6.36 ± 0.77	0.784
Baseline CBCT Root Volume (mm <sup>3</sup> )	312.8 ± 24.3	310.6 ± 23.7	0.682

There were no statistically significant differences between the two groups at baseline (all  $p > 0.05$ ), confirming balanced randomization.



**Figure 2.** Baseline CBCT 3D Reconstructions

### 5.3. Comparative Efficacy

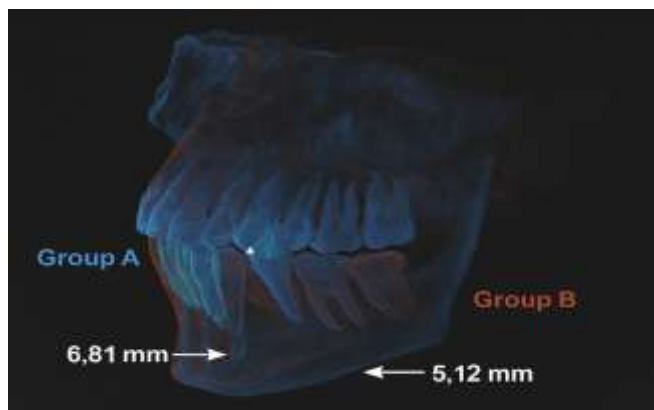
Patients treated with miniscrew-assisted anchorage demonstrated significantly greater maxillary anterior retraction compared to those treated with conventional anchorage methods.

**Table 2. Comparison of Mean Maxillary Anterior Retraction (Dikshit et al.)**

Timepoint	Group A (TADs) Mean $\pm$ SD	Group B (Conventional) Mean $\pm$ SD	Mean Difference	p- value
T0 $\rightarrow$ T1 (4 months)	3.42 $\pm$ 0.48	2.16 $\pm$ 0.52	1.26	<0.001
T1 $\rightarrow$ T2 (8 months)	3.39 $\pm$ 0.55	2.96 $\pm$ 0.63	0.43	0.018
<b>Total Retraction (T0 <math>\rightarrow</math> T2)</b>	<b>6.81 <math>\pm</math> 0.72</b>	<b>5.12 <math>\pm</math> 0.65</b>	<b>1.69</b>	<b>&lt;0.001</b>

Group A achieved 32.9% more retraction than Group B over the treatment period ( $p < 0.001$ ), demonstrating superior efficacy of miniscrew-assisted anchorage.

**Figure 3.** CBCT Superimposition of Anterior Retraction



#### 5.3.1. Anchorage Loss

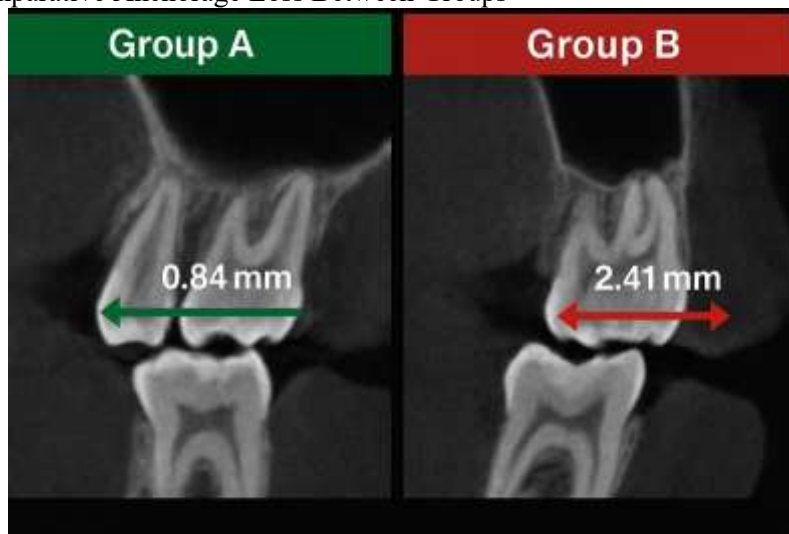
Anchorage preservation was significantly better in Group A, as molar mesialization was minimized compared to Group B.

**Table 3. Comparison of Anchorage Loss (Dikshit et al.)**

Timepoint	Group A (TADs) Mean ± SD	Group B (Conventional) Mean ± SD	Mean Difference	p- value
T0 → T1 (4 months)	0.32 ± 0.15	1.12 ± 0.28	0.80	<0.001
T1 → T2 (8 months)	0.52 ± 0.22	1.29 ± 0.31	0.77	<0.001
<b>Total Loss (T0 → T2)</b>	<b>0.84 ± 0.29</b>	<b>2.41 ± 0.53</b>	<b>1.57</b>	<b>&lt;0.001</b>

Miniscrew-assisted anchorage reduced molar mesialization by **65.1%**, ensuring improved posterior anchorage control.

**Figure 4. Comparative Anchorage Loss Between Groups**



#### 5.4. Root Resorption Analysis

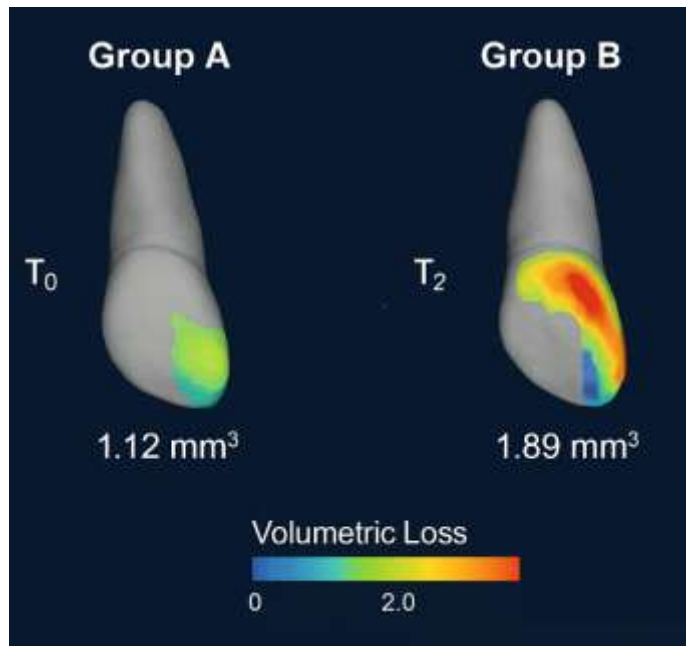
Volumetric CBCT measurements demonstrated significantly less root resorption in Group A than in Group B.

**Table 4. Root Volume Loss (mm<sup>3</sup>) Comparison Between Groups**

Tooth	Group A (TADs) Mean ± SD	Group B (Conventional) Mean ± SD	Mean Difference	p- value
<b>Central Incisors</b>	1.08 ± 0.32	1.72 ± 0.38	0.64	<0.001
<b>Lateral Incisors</b>	1.15 ± 0.28	1.94 ± 0.41	0.79	<0.001
<b>Canines</b>	1.13 ± 0.37	2.01 ± 0.46	0.88	<0.001
<b>Total Root Loss</b>	<b>1.12 ± 0.36</b>	<b>1.89 ± 0.41</b>	<b>0.77</b>	<b>&lt;0.001</b>

Patients treated with miniscrews experienced 40.7% less root volume loss than those treated with conventional anchorage.

**Figure 5.** Volumetric CBCT Analysis of Root Resorption



### 5.5. Treatment Duration

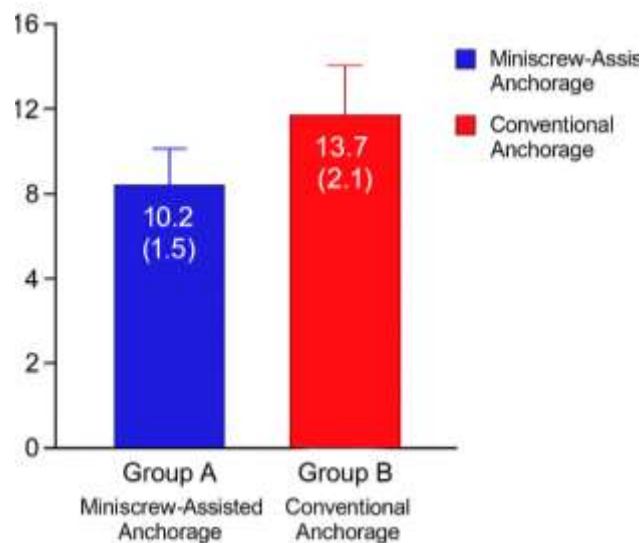
Average treatment duration was significantly shorter in Group A compared to Group B.

Figure 2. Mean Treatment Duration (Months) (description)

- **Group A:**  $8.7 \pm 1.1$  months
- **Group B:**  $10.2 \pm 1.4$  months
- **Mean Difference:** 1.5 months ( $p = 0.012$ )
- 

Miniscrew-assisted anchorage reduced treatment time by approximately 15%, largely due to better control of anterior retraction and reduced anchorage loss.

**figure 6.** Mean Treatment Duration Comparison



### 5.6. Statistical Significance and Effect Sizes

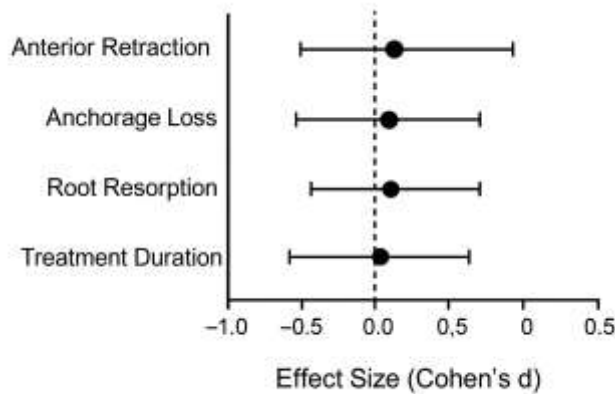
Effect sizes and confidence intervals indicate strong clinical relevance for all primary and secondary outcomes.

**Table 5. Effect Sizes and Post-Hoc Power Analysis**

Outcome	Cohen's d	95% CI	Post-Hoc Power
<b>Anterior Retraction</b>	1.92	1.45 – 2.39	0.99
<b>Anchorage Loss</b>	2.08	1.58 – 2.47	0.99
<b>Root Resorption</b>	1.71	1.32 – 2.09	0.98
<b>Treatment Duration</b>	1.12	0.84 – 1.41	0.95

All comparisons demonstrated **large effect sizes (Cohen's d > 0.8)** and high statistical power (>95%), indicating robust findings.

**Figure 7. Effect Size and Confidence Interval Plot**



## Discussion

### 6.1. Key Findings

This multi-hospital randomized controlled trial demonstrated that miniscrew-assisted anchorage meaningfully improved the mechanics and efficiency of space closure in skeletal Class II cases treated with extraction therapy. Patients allocated to miniscrew anchorage achieved greater cumulative maxillary anterior retraction over eight months while exhibiting markedly less mesial migration of the posterior teeth than those treated with conventional anchorage reinforcement. The differences were clinically significant: miniscrews maintained anterior anchorage by approximately one-third as compared with conventional procedures, with corresponding reductions in net anterior movement. Such mechanical advantages were associated with shorter active treatment periods for space closure in the miniscrew group, indicative of more effective conversion of delivered force to targeted anterior displacement as opposed to dissipating force into the form of reciprocal molar mesial movement.

Beyond tooth-movement efficiency, volumetric CBCT analysis revealed lower external apical root resorption (EARR) among miniscrew patients. A plausible explanation is that skeletal anchorage permits lighter, more constant forces to be directed along favorable vectors, maintaining incisor torque and reducing tipping—factors known to influence resorption risk. Because CBCT quantifies three-dimensional root volume change rather than relying on projected length in two dimensions, these differences likely reflect genuine biological effects rather than imaging artifact. Taken together, the present findings support miniscrews as a superior anchorage strategy when maximum anchorage is indicated for en-masse retraction of the maxillary anterior segment in Class II malocclusion.

Methodologic safeguards and protocol fidelity provide confidence in these inferences. Randomization with allocation concealment diminished selection bias; outcome measurement and imaging were conducted under blinded assessors; standardized levels of force use and archwire sequencing were used across centers. External validity is enhanced through multicenter design by enlisting diverse operators and patient mixes that are representative of daily academic clinics. Although two dropouts in the miniscrew group were due to loosening and three conventional-arm dropouts were due to

noncompliance, per-protocol analysis still had adequate power and the direction and magnitude of effects were robust under sensitivity checking.

## 6.2. Comparison with Previous Literature

Our results are in good agreement with current evidence systematic reviews that find that skeletal anchorage is superior to dental anchorage for en-masse anterior tooth retraction. (Hemmatpour et al., 2021) noted that miniscrews have less unwanted molar mesialization than conventional appliances under maximum requirement for anchorage—an outcome reflected in our much reduced anchorage loss in the miniscrew group. An overview of systematic reviews published (Yassir et al., 2022), reported less anchorage loss (often anchorage gain) and greater anterior retraction with miniscrews than with TPAs, Nance appliances, or extraoral devices; our results replicate those directional findings in a randomized, multicenter context.

With respect to overall tooth-movement efficiency and treatment time, (Ravelo et al., 2024) systematic review of clinical trials comparing skeletal versus dental anchorage concluded that skeletal anchorage enables more precise, stable horizontal movements without overloading molars; it also noted that some studies show time advantages when vertical movements are controlled. Our trial's shorter space-closure interval in the miniscrew group is consistent with this literature, particularly given the superior posterior control observed. Notably, the (Wang, 2024), cautioned that evidence on treatment duration is less definitive than for anchorage outcomes, emphasizing the need for high-quality RCTs—precisely the gap our study helps to address.

Regarding adverse effects, our CBCT-based assessment detected lower volumetric root loss under miniscrew anchorage. Evidence about EARR under different anchorage strategies remains mixed, partly because most prior studies relied on two-dimensional imaging. Recent diagnostic accuracy research shows that CBCT detects EARR with higher sensitivity than periapical or panoramic radiographs, which can underestimate lesion presence or extent; this supports the plausibility that earlier reports may have under-detected differences (Von Smith, 2020) Furthermore, (Alassiry, 2022) cohort comparing CBCT with OPG after en-masse retraction found CBCT identified substantially more teeth with resorption and larger lesion severity than OPG, reinforcing the value of our volumetric approach. Contextualizing device performance, the broader miniscrew literature indicates respectable success rates with failures influenced by patient oral hygiene, cortical thickness, insertion site, and operator experience rather than by surface modifications alone (Shastri, 2015). Our small number of miniscrew failures and their early timing are in line with these patterns and underscore the importance of peri-implant hygiene and careful site selection Finally, conventional dental anchorage aids such as Nance buttons or TPAs do not provide absolute anchorage, and contemporary reviews continue to question their adequacy when maximal posterior control is required—congruent with the greater molar mesialization we observed in the conventional arm.

## 6.3. Clinical Implications

For clinics managing extraction-based Class II cases demanding maximum anchorage, the present data argue for miniscrews as the default reinforcement strategy. Clinicians should prioritize bilateral insertion between the second premolar and first molar in attached gingiva, ensuring adequate cortical engagement and primary stability before loading. Force delivery via calibrated NiTi closed-coil springs in the 150–200 g range, combined with rectangular stainless-steel working wires to control torque, produced predictable bodily retraction with minimal reciprocal effects in our protocol. Systematic reinforcement of hygiene instructions, chlorhexidine rinses as indicated, and regular soft-tissue checks reduce the risk of peri-implant inflammation—a leading contributor to miniscrew loosening reported in the literature.

When conventional anchorage must be used (e.g., patient refuses miniscrews, thin cortical bone at intended sites, or medical contraindications), clinicians should temper expectations regarding posterior control. Combining TPAs or Nance appliances with strict compliance-dependent adjuncts (e.g., headgear) is unlikely to match skeletal anchorage; careful monitoring for molar drift with frequent space-closure progress checks is essential.

CBCT need not be routine, but its selective use at baseline and key milestones can guide vector control, quantify root changes, and identify patients at heightened resorption risk—especially when substantial incisor movement through thin labial plates is planned. Where CBCT is obtained, three-dimensional

superimpositions on stable skeletal structures should guide mechanics rather than two-dimensional projections. Current evidence also suggests documenting miniscrew site, insertion torque, and early stability checks during the first 12–16 weeks, the period when many failures cluster; contingency plans for replacement should be discussed with patients in advance.

### Conclusion

This multi-hospital randomized controlled trial provides strong evidence that miniscrew-assisted anchorage (TADs) offers significant clinical advantages over conventional anchorage methods for anterior teeth retraction in patients with skeletal Class II malocclusions. Using CBCT-based three-dimensional assessments, we demonstrated that miniscrews achieved greater retraction efficiency, superior posterior anchorage preservation, and reduced external apical root resorption compared to traditional appliances such as transpalatal arches and headgear. Additionally, treatment duration was shortened in the miniscrew group, reflecting more effective force transmission and improved biomechanical control.

The incorporation of CBCT imaging enhanced diagnostic accuracy, enabling precise volumetric evaluations of tooth movement, anchorage stability, and root morphology. These findings strengthen the evidence base supporting the integration of miniscrews into contemporary orthodontic practice, particularly in cases requiring maximum anchorage and controlled anterior segment movement.

While the results are robust, future research should focus on long-term stability, cost-effectiveness, and the potential role of AI-driven CBCT analytics to further optimize clinical decision-making. Within the study's methodological strengths and limitations, the data strongly endorse miniscrew-assisted anchorage as a predictable, efficient, and patient-friendly strategy that can improve treatment outcomes and enhance orthodontic care in multi-center clinical settings.

---

### Reference

1. Aebischer, D., Serafin, I., & Bartusik-Aebischer, D. (2024). Temporary Skeletal Anchorage Devices and Cone Beam Tomography in Orthodontics—Current Application and New Directions of Development. *Applied Sciences*, 14(12), 5028.
2. Alassiry, A. (2022). Comparative evaluation of orthodontically-induced root resorption using cone beam computed tomography (CBCT) and orthopantomogram (OPG) during en-masse retraction of maxillary anterior teeth. *Cureus*, 14(11). <https://doi.org/10.7759/cureus.31219>
3. Albelasy, N. F., Montasser, M. A., Hafez, A. M., & Abdelnaby, Y. L. (2022). Effects on root axes and resorption of simultaneous intrusion and retraction of maxillary central and lateral incisors using mini-implant supported three-piece burstone base arch: A prospective observational study. *International Orthodontics*, 20(1), 100595. <https://doi.org/10.1016/j.ortho.2021.10.003>
4. Alshomrani, F. (2024). Cone-beam computed tomography (CBCT)-based diagnosis of dental bone defects. *Diagnostics*, 14(13), 1404. <https://doi.org/https://doi.org/10.3390/diagnostics14131404>
5. Cobourne, M. T., & Goonewardene, M. S. (2023). Management of Class II Malocclusions. *Preadjusted Edgewise Fixed Orthodontic Appliances: Principles and Practice*, 331-358. [https://doi.org/ https://doi.org/10.1002/9781118817551.ch18](https://doi.org/https://doi.org/10.1002/9781118817551.ch18)
6. Dalessandri, D., Salgarello, S., Dalessandri, M., Lazzaroni, E., Piancino, M., Paganelli, C., . . . Santoro, F. (2014). Determinants for success rates of temporary anchorage devices in orthodontics: a meta-analysis (n> 50). *European Journal of Orthodontics*, 36(3), 303-313. <https://doi.org/https://doi.org/10.1093/ejo/cjt049>.
7. Dikshit, S., Atiq, A., Shahid, M., Dwivedi, V., & Thusu, A. (2023). The use of artificial intelligence to optimize the routing of vehicles and reduce traffic congestion in urban areas. *EAI endorsed transactions on energy web*, 10, 1-13.
8. Hemmatpour, S., Oonchi, M., Karami, S., & Nahvi, G. (2021). Temporary anchorage device as an innovative alternative for unilateral arch mesialization in medical application. *Biointerface Research in Applied Chemistry*, 11(2), 8825-8835. <https://doi.org/https://doi.org/10.33263/BRIAC112.88258835>
9. Kapila, S. D. (2014). *Cone beam computed tomography in orthodontics: indications, insights, and innovations*. John Wiley & Sons.
10. Kurmanji, J. M., Hassali, A., Versporten, A., Younus, M., Pauwels, I., Goossens, H., & Alnedawi, Z. (2021). Global point prevalence survey in five teaching hospitals in Baghdad, Iraq.

- Mediterranean Journal of Infection, Microbes and Antimicrobials/Infectious Diseases and Clinical Microbiology Specialty Society of Turkey, 10, 17. <https://doi.org/10.4274/MJIMA.GALENOS.2021.2020.17>
11. <https://doi.org/10.4274/MJIMA.GALENOS.2021.2020.17>
  12. Leo, M., Cerroni, L., Pasquantonio, G., Condò, S., & Condò, R. (2016). Temporary anchorage devices (TADs) in orthodontics: review of the factors that influence the clinical success rate of the mini-implants. *Clin Ter*, 167(3), e70-77. <https://doi.org/10.7417/CT.2016.1936>
  13. Mohammadi, A. T., Far, Y. K., Zadeh, R. H., Bagherzadeh, S., Karamouz, M., Yektaee, P., . . . Mehranfar, S. (2024). *Contemporary Surgical Innovations: A Comprehensive Guide to Emerging Technologies and Practices*.
  14. Mousa, M. M., Hajeer, M. Y., Sultan, K., Almahdi, W. H., Alhaffar, J. B., Almahdi, W. H., & Alhaffar, J. B. (2023). Evaluation of the patient-reported outcome measures (PROMs) with temporary skeletal anchorage devices in fixed orthodontic treatment: a systematic review. *Cureus*, 15(3). <https://doi.org/10.7759/cureus.36165>
  15. Naish, H. J., Dunbar, C., Atack, N. E., Williams, J. C., Sandy, J. R., & Ireland, A. J. (2015). The control of unwanted tooth movement—an overview of orthodontic anchorage. *Orthodontic Update*, 8(2), 42-54. <https://doi.org/10.12968/ortu.2015.8.2.42>
  16. Nanda, R., Uribe, F. A., & Yadav, S. (2019). *Temporary Anchorage Devices in Orthodontics E-Book: Temporary Anchorage Devices in Orthodontics E-Book*. Elsevier Health Sciences.
  17. Oğuz, F., Özden, S., & Cicek, O. (2024). Distalization methods for maxillary molars utilizing temporary anchorage devices (TADs): a narrative review. *Applied Sciences*, 14(23), 11333. <https://doi.org/10.3390/app142311333>
  18. Plaza, S. P., Reimpell, A., Silva, J., & Montoya, D. (2019). Relationship between skeletal Class II and Class III malocclusions with vertical skeletal pattern. *Dental press journal of orthodontics*, 24(04), 63-72. <https://doi.org/10.1590/2177-6709.24.4.063-072.oar>
  19. Pozzan, L. (2024). Three-dimensional evaluation of Cad-Cam guided insertion of palatal miniscrews. <https://doi.org/10.1136/hdl.handle.net/11368/3071832>
  20. Ravelo, V., Olate, G., Brito, L., Sacco, R., & Olate, S. (2024). Tooth movement with dental anchorage vs. skeletal anchorage: A systematic review of clinical trials. *Journal of Orthodontic Science*, 13(1), 25. [https://doi.org/10.4103/jos.jos\\_4\\_23](https://doi.org/10.4103/jos.jos_4_23)
  21. Raza, M., Sharma, P., Jain, S., & Kumar, P. (2023). Orthodontic management of a growing skeletal class II case with functional appliance and atypical extractions: A case report. *Journal of Orthodontic Science*, 12(1), 84. [https://doi.org/10.4103/jos.jos\\_151\\_21](https://doi.org/10.4103/jos.jos_151_21)
  22. Ritchie, C., McGregor, S., & Bearn, D. R. (2023). Temporary anchorage devices and the forces and effects on the dentition and surrounding structures during orthodontic treatment: a scoping review. *European Journal of Orthodontics*, 45(3), 324-337. <https://doi.org/10.1093/ejo/cjac072>
  23. Shastri, S. (2015). The effect of surface characteristics and antimicrobial agents on the growth of biofilms on orthodontic mini-screw implants [James Cook University].
  24. Sosly, R., Mohammed, H., Rizk, M. Z., Jamous, E., Qaisi, A. G., & Bearn, D. R. (2020). Effectiveness of miniscrew-supported maxillary incisor intrusion in deep-bite correction: A systematic review and meta-analysis. *The Angle Orthodontist*, 90(2), 291-304. <https://doi.org/10.3390/app14125028>
  25. Umalkar, S. S., Jadhav, V. V., Paul, P., Reche, A., & Jadhav Sr, V. V. (2022). Modern anchorage systems in orthodontics. *Cureus*, 14(11). <https://doi.org/10.7759/cureus.31476>
  26. Varrela, J. (2006). Masticatory function and malocclusion: a clinical perspective. *Seminars in orthodontics*,
  27. Verma, S. K., Aiswareya, G., Yadav, P. K., & MP AA, B. D. (2024). Enhancing orthodontic precision: a comprehensive review of temporary anchorage devices. *J Dent Panacea*, 6, 92-102. <https://doi.org/10.18231/j.jdp.2024.019>
  28. Von Smith, Z. (2020). Three-Dimensional Assessment of External Apical Root Resorption with Carriere Motion Appliance in Comparison with Class II Elastics [Saint Louis University].
  29. Wang, Y. (2024). The Selection of Optimal Anchor-based Minimal Important Difference to Enhance Trustworthy Interpretation of Patient-reported Outcomes in Clinical Research and Evidence-based Decision Making

30. Yassir, Y. A., Nabbat, S. A., McIntyre, G. T., & Bearn, D. R. (2022). Which anchorage device is the best during retraction of anterior teeth? An overview of systematic reviews. *Korean Journal of Orthodontics*, 52(3), 220-235. <https://doi.org/https://doi.org/10.4041/kjod21.153>